Elastic Compression of Bioengineered Human Skin Substitute Improves Chronic Ulcer Healing: Fuzzy Yarn Compression Controls Wound Bed Edema

Insulin dependent diabetic treated 5 months in a rural hospital wound center with medical honey

Diabetic Ulcers

Problems

- Diabetic, on insulin
- Lateral ankle ulcers
- Pedal pulses present
- Healing stalled in spite of community wound center therapy with use of honey for 5 months

Left ankle lateral ulcers present for 5 months. Treated at community wound center with honey dressing. Observe shiny edematous granulation tissue, macerated skin edges, transparent skin around wounds and adherent fibrin bioburden. Bacteria in the thick biofilm are likely culprits for stalled healing.

Acoustic powered debridement of painful lateral ankle diabetic ulcer cleans up fibrinoid bioburden.

Note corrosive furrows in the skin around the ulcers. Fuzzy Yarns in Longitudinal Yarn Compression (LYC) textile creates furrows in the skin.

Rx

- Bioengineered human skin substitute(*)
- Hypochlorous acid solution lavages(**)
- Acoustic powered(***) debridements
- HEMA Nanoparticle Power dressings(****)
- Longitudinal Yarn Compression Textile(*****)

Outcome

- Ulcers healed with 12 weeks of Longitudinal Yarn Compression and bioburden control
- Ulcers healed 9 weeks after Bioengineered Human Skin Substitute

Complete healing 9 weeks after bioengineered human skin substitute.

Right 5th metatarsal head ulcer is accompanied by extensive edema.

Ischemic Ulcer

Problems

- Recurrent R foot ulcers
- No healing progress over 7 months
- Paraplegia
- NPWT x 2 months
- Atherosclerosis, absent pedal pulses
- L BKA, Refuses R BKA.

Foot is deformed due to paraplegia. Foot is painful due to ischemia from aorto-iliac and femoral-popliteal atherosclerotic occlusions. Observe the heavy bioburden, heavy exudates, extensive edema and erythemia suggesting cellulitis. Two surgeon consultants recommend R BK Amputation.

HEMA nanoparticle powder is applied between Longitudinal Yarn Compression textile yarns after weekly wound debridement.

Note LYC stockinet is in direct contact with the granulation surface. LYC is layer one of a four layer dressing.

Longitudinal Yarn Compression textile creates furrows in wound granulations. Note decrease in edema after two weeks of treatment. LYC compression appears to increase skin perfusion. HEMA powder dressing helped control wound pain. Note the corrosive furrows in the granulation wound.

HEMA nanoparticle gel on granulating surface. Note improved appearance of skin.

Rx

- Longitudinal Yarn Compression as the first layer of a four layer dressing(*****).
- HEMA nanoparticle gel(****).
- Bioengineered human skin substitute (*).
- Weekly mechanical control of biofilm with Hypochlorous acid solution(**) and 22.5 KHz ultrasound debridement(***).

Outcome

- Rapid 85% healing ischemic ankle ulcer after BeSS grafting.
- Failed mid-foot split thickness skin graft.
- Complete healing 5th metatarsal head ulcer.
- Good control of pain.

5th metatarsal head ulcer healed 3 week after Bioengineered human skin substitute.

Extensor surface ulcer is 9 weeks post split thickness wound center pinch skin graft. Note the pinch graft failed while the bioengineered human skin substitute healed the other two ulcers.

Ankle Ulcer 80% healed 7 weeks post BeSS. Note how robust the skin looks as a result of Longitudinal Yarn Compression textile.

Recurrent painful left leg stasis ulcers make the patient miserable.

Recurrent Stasis Ulcer

Problems

- Recurrent L leg stasis ulcers
- Poorly controlled diabetes

Week two of therapy, severe stasis dermatitis with weeping serum and heavy bioburden.

Severe stasis dermatitis with weeping serum and heavy bioburden.

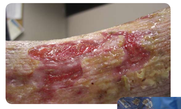

Note the corrosive furrows in the skin surrounding the healing stasis ulcers.

Ultrasonic powered debridement at 7 weeks of compression therapy.

Bioengineered Human Skin Substitute (BeSS) is placed after 7 weeks of compression with fuzzy yarn.

Polyester gauze(**) protects BeSS. Longitudinal Yarn Compression (LYC) stockinet is the base layer of a four layer dressing. LYC speeds healing of the BeSS graft.

Rx

- Longitudinal Yarn Compression(*****) textile for treatment of stasis dermatitis for 11 weeks.
- Sharp and later Acoustic powered(***) weekly debridements.
- Bioengineered human skin substitute(*). For the primary dressing, LYC was used as the first layer of a four layer dressing.

Outcome

- LYC stockinet treats stasis dermatitis.
- Wounds heal seven weeks after human skin substitute.

Wounds are 97% healed seven weeks after BeSS. Note skin corrosive furrows in the granulating wounds.

A veteran of the U.S. Army Air Corps who served in occupied Japan has had a 10 month unrequited relationship with a local wound care center. Enzyme debridement had not been effective. Pedal pulses were present. Patient takes Prednisone 5mg daily for COPD.

Painful Bilateral Stasis Ulcer

Problems

- Venous insufficiency
- Atherosclerosis
- On Prednisone for emphysema

Wounds at first clinic visit. Note how thin the skin appears. Patient is on Prednisone for COPD. Note edema of the surrounding skin.

Wounds at first clinic visit. Wounds have been treated with collagenase at another wound clinic for several months. Wounds were weeping lymph fluid. Note severe stasis dermatitis. The shiny red skin reflects light and has a glassy appearance because of edema fluid in the dermis that refracts the reflected light.

Incomplete debridement of wounds at first clinic visit with scalpel and curette. Patient was acutely short of breath and debridement was halted.

Longitudinal Yarn Compression (LYC) textile directly compresses the granulation wound surface as the first layer of a four layer dressing.

LYC stockinet was placed directly on granulation ulcers. Note gauze is on top of the stockinet yarns, held in place with nylon stockings.

Bioengineered Human Skin Substitute placed after 7 weeks of compression-focused compression with LYC stockinet. Note how robust the skin appears after clearing the dermatitis with compression. Note also the corrosive furrows in the skin surrounding the ulcers.

Rx

- Compression with Longitudinal Yarn Compression(*****) (LYC) textile for four months to control severe stasis dermatitis.
- Two applications of Bioengineered Human Skin Substitute(*). LYC textile was used as a primary dressing after the second BeSS application.

Outcome

- Nanoparticle Polymer Powder Gel Controls Ulcer Pain
- Longitudinal Yarn Compression Stockinet (LYC) in Direct Contact with Granulation Tissue Speeds Healing
- Ulcers Healing, at Time of Publication, After 17 Days of Longitudinal Yarn Compression.

Left leg CSU's "healed" after LYC for 7 months and two applications of BeSS.

Legend

* Apligraf®, Organogenesis, Canton, MA

** Vashe® Wound Therapy, PuriCore, Malvern, PA

*** SonicOne®, Misonix, Farmingdale, NY

**** Altrazeal™, Oluru Corporation, Addison, TX

***** EdemaWear®, Compression Dynamics, LLC, Omaha, NE

Authors:

Martin J. Winkler, MD, FACS

Steven L. Clinch, MD, FACS

Karla A. Manzel, BSN, MS, CWON, FCN

Lindsey Manzel, BS

Elastic Compression of Bioengineered Human Skin Substitute Improves Chronic Ulcer Healing: Fuzzy Yarn Compression Controls Wound Bed Edema

Introduction: Lymphatic insufficiency accompanies Chronic Stasis Ulcers (CSU), creating an edematous wound hostile to skin graft healing. Bioengineered skin substitute (BeSS) [1] reliably "heals" CSU hostile wound beds that wound not "take" a split thickness skin graft. Negative wound pressure therapy (NWPT), and three layer compression dressings speed healing of hostile wounds treated with BeSS, presumably by controlling pathological edema at the wound surface.(1)

Yarn Focused Compression (YFC) textile creates corrrow furrows in the subcutaneous fat beneath fuzzy yarns. YFC, at a physiological level, is a novel elastic compression textile for edema control.(2) Landon delivered yarn focused elastic compression, with YFC resting directly on granulating CSU surface and showed increased healing.(3) Maloley reported improved split thickness skin graft healing when yarn focused elastic compression is applied at the first dressing change.(4)

This study answers two questions about BeSS therapy for CSU: Is YFC textile a feasible and safe primary dressing for CSU treated with BeSS? Does the control of healing wound surface edema with Yarn Focused Compression improve BeSS healing?

Methods: Four patients with skin ulcers of mixed etiology, were treated with BeSS[1] held in place with nanoparticle hydrogel[****], a thin polyester mesh[******] and YFC textile[*****] as a fuzzy compressive first layer of a three layer dressing.

Results: YFC compression textile was well tolerated. Ulcer healing is documented in photos. Dislodgement of the dressing protecting the BeSS was the only complication.

Conclusions: Elastic compression of BeSS grafted ulcers with Yarn Focused Compression textile appears to be comfortable and safe. Controlling healing surface edema that accompanies stasis ulcers with Yarn Focused Compression textile may improve ulcer healing rates with Bioengineered Skin Substitute.

References:

(1) Espensen, EH, et al. "Use of subatmospheric (VAC) therapy to improve bioengineered tissue grafting in diabetic foot wounds." Journal of the American Podiatr. Med. Assoc. 92(7): 395-397, 2002.

(2) Kozeny, D., Stott, K. "Longitudinal yarn compression textile: An innovative treatment for leg swelling." Journal of Vascular Nursing, Volume 25, Issue 3, Pages 62-62, September 2007.

(3) Landon, Laura, et al. "Controlling wound edema with fuzzy yarn focused elastic compression in direct contact with granulation tissue speeds healing." Clinical Symposium on Advances in Skin & Wound Care Abstract October 2009.

(4) Maloley, Brittney J., et al. "Improved skin graft maturation and cosmesis with yarn focused elastic compression." American College of Surgeons, Poster Session, October 2009.

National Science Foundation
Grant Award Number 0650233

University of Nebraska Medical Center

Creighton University School of Medicine

www.CompressionDynamics.com